

Review Article

Retinoblastoma : Recognise the Disease early and save a child's life

Swathi Kaliki

Abstract : Retinoblastoma is the most common malignant intraocular tumor of childhood, with an incidence of 1 in 16,000 to 18,000 live births. The most common symptoms of retinoblastoma are leukocoria and strabismus. The diagnosis of retinoblastoma is delayed in the developing countries when compared to that of developed countries. The management of retinoblastoma has dramatically changed over the years from previous radiotherapy methods to current chemotherapy strategies. The treatment of choice in less advanced cases is chemotherapy and in more advanced cases is enucleation. With the improved treatment strategies, patient survival, globe salvage, and vision salvage in patients with retinoblastoma has drastically improved over the years. The aim of this article is to discuss the presenting features, treatment strategies, and prognosis of retinoblastoma.

Key Words : Eye Tumor, Retinoblastoma, Radiotherapy, Chemotherapy, Enucleation

Introduction

Retinoblastoma is the most common malignant intraocular tumor of childhood. James Wardrop first described it as a clinical entity in 1809, and Verhoeff proposed the term retinoblastoma in 1922, which was adopted by the American Ophthalmological Society in 1926^{1,2}.

Incidence of retinoblastoma

The incidence of retinoblastoma is 1 in 16,000 to 1 in 18,000 live births^{3,4}. It represents 11% of cancers developing in the first year of life, and 3% of the cancers developing among children younger than 15 years⁵. It is estimated that, worldwide, 7202 to 8102 new cases are detected each year, of which 5819 to 6545 cases (81% cases) are from Africa and Asia⁶.

Pathogenesis of retinoblastoma

Retinoblastoma is a hereditary malignancy with approximately 40% cases having an inherited form of disease caused by heterozygous germline mutation in the RB gene (RB1). Knudson proposed the "two-hit hypothesis" to explain the pathogenesis of retinoblastoma.⁷ Ten percent of patients have familial retinoblastoma, who inherit RB1 mutation from a genetically affected parent. In such cases, every cell in the body of affected children contains a germline RB1 mutation (the first hit). Mutation of the remaining RB1 gene copy in a retinal cell (the second hit) causes retinoblastoma.⁸ In another 30% of children

with sporadic hereditary retinoblastoma, the germline RB1 mutation occurs as a de novo genetic event and their parents are genetically normal⁹. The remaining 60% children have sporadic nonhereditary retinoblastoma, in which the tumors occur due to two somatic RB1 mutations in a single retinal progenitor or precursor cell. Based on the hereditary and inheritance pattern, retinoblastoma is classified as somatic or germline, sporadic or familial, and nonhereditary and hereditary.

Signs and symptoms

Retinoblastoma is usually diagnosed between the ages of 3 months to 3 years, with 95% of cases diagnosed before the age of 5 years^{10,11}. In rare instances, the tumor can be detected at birth or in adulthood. The tumor can be unilateral or bilateral. Overall, the mean age at presentation of retinoblastoma is 18 months. The mean age at presentation of unilateral cases is 24 months and for bilateral cases is 12 months^{10,11}.

The most common presenting complaint in children with retinoblastoma is leukocoria or a white pupillary reflex (60% to 70% cases). The second most common complaint is strabismus (20% to 25% cases).^{11,12} The other less common presenting features include pseudohypopyon, hyphema, heterochromia iridis, unilateral mydriasis, red painful eye, proptosis, and orbital cellulitis (Figure 1). However, in contrast to the reports from the developed countries, the reports from some of the developing countries suggest proptosis as the most common presenting feature of retinoblastoma (55% to 85%), indicating a delayed diagnosis of the disease in the developing world^{13,14}.

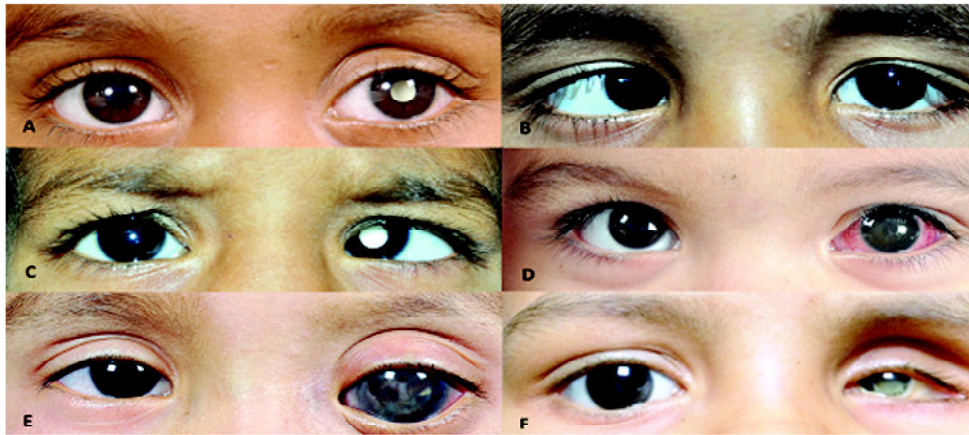

Figure 1: Presenting features of retinoblastoma

- (A) White pupillary reflex or leukocoria of the left eye
- (B) Strabismus of the right eye
- (C) Leukocoria with strabismus of the left eye
- (D) Red painful left eye
- (E) Enlarged left eyeball
- (F) Phthisis bulbi of the left eye

Retinoblastoma presents with a solid retinal tumor, with or without subretinal seeds and / or vitreous seeds. Solid retinal tumors begin as a small translucent thickening of the sensory retina, and gradually enlarge to an opaque yellowish-white lesion with intralesional vascularity and dense chalky white areas of calcification¹¹. The lesions can be focal or multifocal. As the tumors enlarge, the tumor cells disseminate into the surrounding tissues with seeding of the tumor in the vitreous (vitreous seeds) and the subretinal space (subretinal seeds). Endophytic tumor growth pattern is associated with vitreous seeds and exophytic tumor growth pattern is associated with retinal detachment and subretinal seeds. Advanced cases can present with extension of the tumor into the anterior chamber (pseudohypopyon), along the optic nerve, and / or with extraocular tumor extension.

Ancillary tests

The most important tool in the diagnosis of retinoblastoma is indirect ophthalmoscopy. The other useful tests include ultrasonography, computed tomography, and magnetic resonance imaging. B-scan ultrasonography reveals a dome shaped or irregular intraocular mass. On A-scan ultrasonography, the noncalcified portion of the tumor demonstrates low to medium internal reflectivity, and the areas of calcium within the lesion exhibit high reflective echoes causing attenuation of the adjacent sclera and orbit¹⁵. Ultrasonography is also useful to measure the tumor thickness.

Computed tomography (CT) of the orbit helps in the detection of intraocular mass with intratumoral calcification, extension of tumor into optic nerve and extraocular tumor extension. CT orbit is more sensitive in the detection of intratumoral calcification, which is seen as bright hyperdense spots¹⁶. On magnetic resonance imaging (MRI) of the orbit, retinoblastoma is hyperintense to vitreous on T1, and hypointense on T2-weighted images¹⁶. MRI is more sensitive in the detection of choroidal and/or optic nerve tumor infiltration. CT and MRI brain are also useful in the detection of pinealoblastoma.

Classification and staging of retinoblastoma

Over the years, several classification systems have been used for retinoblastoma. Intraocular retinoblastoma has been classified using Reese-Ellsworth classification, Essen classification, Philadelphia classification, and International Classification of Retinoblastoma. The most commonly used classification for intraocular retinoblastoma is International Classification of Retinoblastoma (Figure 2), which includes five groups:^{17,18}

Group A: Small tumor ≤ 3 mm located outside the macula

Group B: Larger tumor > 3 mm or any tumor with associated subretinal fluid or any tumor in the macula

Group C: Tumor associated with focal subretinal and/or vitreous seeds

Group D: Tumor associated with diffuse subretinal and/or vitreous seeds

Group E: Massive tumor with neovascular glaucoma, opaque media due to intraocular hemorrhage, diffuse infiltrating tumor, aseptic orbital cellulitis, or phthisis bulbi.

For tumors with intraocular and extraocular involvement, the described classifications include Grabowski-Abramson classification, St Jude classification, International Retinoblastoma Staging System, and the TNM (Tumor, node, metastasis) classification.

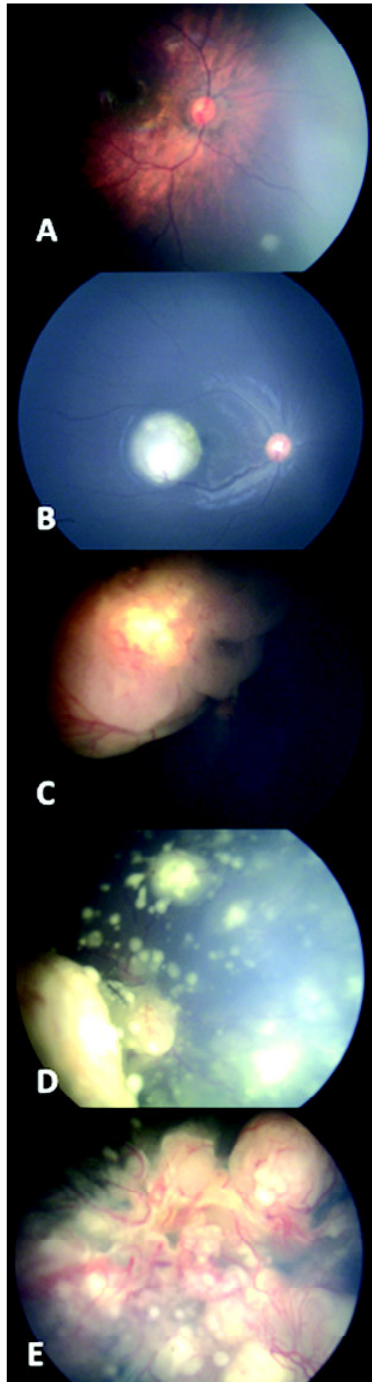


Figure 2: International classification of retinoblastoma
 (A) Group A with tumor < 3 mm in size
 (B) Group B with tumor > 3 mm in size
 (C) Group C with solid tumor associated with focal subretinal seeds
 (D) Group D with solid tumor associated with diffuse vitreous seeds
 (E) Group E tumor with diffuse tumor filling the globe

The most commonly used classification for extraocular retinoblastoma is International Retinoblastoma Staging System, which includes four stages:¹⁹

Stage 0 : Intraocular retinoblastoma, eye not enucleated

Stage I : Eye enucleated, no residual tumor

Stage II : Eye enucleated, microscopic residual tumor

Stage III: Local/regional disease

a : Overt orbital disease

b : Local/regional lymph node involvement

Stage IV: Metastatic disease

a : Hematogenous metastasis (without central nervous system (CNS) involvement)

1. Single lesion

2. Multiple lesions

b : Central nervous system involvement

1. Prechiasmatic lesion

2. CNS mass

3. Leptomeningeal and cerebrospinal fluid disease

Treatment of retinoblastoma

The treatment of retinoblastoma depends on the tumor laterality and the tumor grouping/staging. The various forms of treatment for retinoblastoma include:

Local treatment : Laser photocoagulation

Transpupillary thermotherapy

Cryotherapy

Chemotherapy : Periocular chemotherapy

Intravitreal chemotherapy

Intraarterial chemotherapy

Systemic chemotherapy

Radiation treatment : Plaque radiotherapy

External beam radiotherapy

Proton beam radiotherapy

Surgical treatment : Enucleation

Orbital exenteration

Laser photocoagulation

Xenon, Argon, and YAG lasers have been used for laser photocoagulation. Laser photocoagulation can be used for a small tumor < 3 mm in basal diameter and < 2 mm in thickness²⁰. The spot size is 200-300 um and the power is 100 to 400 mw. Laser burns are applied around the tumor in a double row fashion. The end point of laser photocoagulation is a grey-white burn. Two to three sessions at 4-week intervals are required to attain tumor

control. The aim of this therapy is to occlude the blood supply to the tumor, to cause tumor regression. Laser photocoagulation should be avoided during systemic/intrarterial chemotherapy as it decreases the drug delivery to the tumor. With the advent of transpupillary thermotherapy with diode laser, argon laser photocoagulation is less commonly used.

Transpupillary thermotherapy

Transpupillary thermotherapy (TTT) can be used as primary treatment for small tumors (< 3 mm in basal diameter and < 2 mm in thickness) or as consolidation treatment during systemic chemotherapy²¹. 810 nm diode laser is used to achieve hyperthermia and allow tumor destruction. The diode laser can be delivered to the tumor through a microscope adaptor or an indirect ophthalmoscope. When used with indirect ophthalmoscope, the spot size is 1.2 mm and the power is 300 to 800 mw. The laser burns are applied over the tumor. The end point of TTT is a grey-white burn. The preferred duration of treatment during each session is 5 to 7 minutes. Two to three sessions at 4 to 6-week intervals are required to attain tumor control, when used as primary treatment. When combined with systemic chemotherapy (Chemothermotherapy), TTT is performed after 1 to 2 hours of administration of systemic chemotherapy²¹. A mean of 3 to 4 sessions are required to achieve adequate tumor control.

Cryotherapy

Cryotherapy is used to treat small tumors (< 3 mm in basal diameter and < 2 mm in thickness) in the pre-equatorial region. Triple freeze-thaw cryotherapy is advocated in the management of retinoblastoma²². Single or triple freeze-thaw cryotherapy at 1 or 2 locations administered 24 hours prior to systemic chemotherapy increases the permeability of carboplatin into the vitreous by 15-folds and thus allows better tumor control²³.

Periocular chemotherapy

Periocular administration of chemotherapy allows delivery of higher concentrations of chemotherapy drugs to the posterior segments of the eye. Periocular chemotherapy is used as an adjunct treatment for eyes with persistent vitreous seeding despite other forms of treatment, in patients with bilateral retinoblastoma with poor prognosis at diagnosis, or in those in whom systemic chemotherapy is contraindicated. The most commonly used drug is

carboplatin at a dose of 20mg/2cc. The administration of periocular carboplatin results in higher vitreous concentration of carboplatin by 8 to 10-fold when compared to intravenous administration.²⁴

Intravitreal chemotherapy

Intravitreal chemotherapy for retinoblastoma was first investigated in 1960's. However, this technique did not gain popularity due to risk of tumor seeding after any intraocular intervention in retinoblastoma. Recently, intravitreal chemotherapy is being used in the treatment of residual/recurrent vitreous seeds. The most commonly used drug for intravitreal injection is melphalan at a dose of 20-30 ug. The drug is given via the pars plana route and is repeated every 7 to 10 days or every month^{25,26}.

Intraarterial chemotherapy

Intraarterial chemotherapy for retinoblastoma involves injection of chemotherapeutic agent directly into the ophthalmic artery, thus allowing targeted drug delivery into the eye²⁷. It can be used as primary or secondary treatment for retinoblastoma. The most commonly used drug for intraarterial chemotherapy is melphalan at a dose of 5mg/30 cc normal saline. The advantages of intraarterial chemotherapy include :

1. Control of intraocular tumor
2. Resolution of Retinal Detachment
3. Globe salvage
4. Minimal systemic side-effects

Systemic chemotherapy

Systemic intravenous chemotherapy is used for chemoreduction of intraocular tumors to facilitate globe and vision salvage, in orbital extention to control the malignancy prior to enucleation or exenteration, for chemoprophylaxis in eyes with high-risk retinoblastoma to prevent systemic metastasis, and for treatment of metastatic retinoblastoma²⁸⁻³². The most commonly used chemotherapeutic regimen to achieve chemoreduction is vincristine sulfate, etoposide phosphate and carboplatin (VEC) for 6 cycles every 3-4 weeks. The advantages of systemic chemotherapy include :

1. Control of intraocular tumor
2. Resolution of retinal detachment
3. Globe salvage
4. Vision salvage
5. Prevention of pinealoblastoma

6. Prevention of systemic metastasis in high-risk retinoblastoma, and
7. Reduction of long-term second non-ocular cancers.

Plaque radiotherapy

Plaque radiotherapy is used as primary treatment for unilateral solitary tumors and most commonly as secondary treatment for recurrent or residual tumors. The size of the episcleral plaque is planned such as to cover 2 mm margin beyond the tumor basal dimension all around the lesion. The tumor apex dose is 40 Gy with a 2 mm safety margin at the tumor apex. The advantages of plaque radiotherapy include:

1. Control of intraocular tumor
2. Resolution of retinal detachment
3. Globe salvage
4. Shorter duration of treatment
5. Minimal side-effects due to minimal exposure of normal tissue outside the radiation field
6. No risk of second malignancies due to radiation exposure

External beam radiotherapy

External beam radiotherapy (EBRT) was the most common modality of primary treatment for retinoblastoma in the pre-chemotherapy era. With the improved chemotherapeutic options, EBRT is rarely used as primary treatment. Currently, it is reserved for cases with poor response to systemic chemotherapy, eyes with extensive subretinal and/or vitreous seeds not responding to other forms of treatment, as an adjunct treatment in cases with extension of tumor to optic nerve transection or those with extraocular tumor extension. A total dose of 40 to 45 Gy is delivered to the eye in multiple fractions³³. Though satisfactory tumor control is achieved with EBRT, it is associated with significant adverse effects such as:

1. Dry eye
2. Radiation induced cataract
3. Radiation retinopathy and/or maculopathy
4. Radiation optic neuropathy
5. Orbital hypoplasia
6. Second malignancies due to radiation exposure in patients with germline mutation

The adverse effects are minimal with the newer modifications of EBRT including 3 dimensional conformal radiotherapy and intensity modulated radiation therapy.

Proton beam radiotherapy

Proton beam radiotherapy can also be used for the treatment of retinoblastoma. The indications of treatment are similar to external beam radiotherapy. Tumor control with proton beam radiotherapy is comparable to that achieved with EBRT, and is associated with lower incidence of radiation-induced side-effects.

Enucleation

Prior to the advent of radiotherapy and chemotherapy, enucleation was the most commonly used modality of treatment for intraocular retinoblastoma. Despite recent advances in the management of retinoblastoma, enucleation remains the treatment of choice in cases with advanced tumors. The indications of enucleation include group E tumors, tumors not responding to conservative treatment, and in those eyes with optic nerve and/or extraocular tumor extension after neoadjuvant chemotherapy. Adequate care should be taken during enucleation to avoid perforation of the globe and obtain a long segment of optic nerve.

Following enucleation, the histopathologic features are determined. The high-risk histopathologic features predictive of systemic metastasis include:³⁴

1. Anterior chamber seeding
2. Iris infiltration
3. Ciliary body infiltration
4. Massive choroidal infiltration (≥ 3 mm in largest dimension)
5. Combined choroidal and optic nerve involvement
6. Retrolaminar optic nerve involvement
7. Involvement of optic nerve transection
8. Scleral involvement
9. Extrascleral involvement

The patients with high-risk retinoblastoma are treated with 6 cycles of adjuvant systemic chemotherapy at 3-week intervals. In cases with involvement of optic nerve transection, full thickness sclera, and extraocular tissue, additional EBRT is recommended.

Orbital exenteration

Orbital exenteration for retinoblastoma is indicated in those cases with orbital tumor extension. With the advent of systemic chemotherapy, primary orbital exenteration is rarely required. The cases with orbital tumor extension become amenable to enucleation with neoadjuvant

systemic chemotherapy, and exenteration is performed in those cases with persistent extraocular tumor despite systemic chemotherapy.

Prognosis

It is estimated that, worldwide, 3001 to 3376 patients die every year, due to retinoblastoma, of which 2845 to 3201 patients (95% cases) are from Africa and Asia⁶. While the mortality rate due to retinoblastoma is 3 to 5% in developed countries, it is 70% in Africa, and 39% in Asia. With early diagnosis and appropriate treatment, the survival rates of children with retinoblastoma can be improved.

References

1. Wardrop J. Observations on fungus hematodes or soft cancer. Edinburg: George Ramsay and Co; 1809.
2. Verhoeff FH, Jackson E. Minutes of the proceedings of the 62nd annual meeting. Trans Am Ophthalmol Soc 1926;24:38-43.
3. Broaddus E, Topham A, Singh AD. Incidence of retinoblastoma in the USA: 1975-2004. Br J Ophthalmol 2009;93(1):21-3.
4. MacCarthy A, Draper GJ, Steliarova-Foucher E, Kingston JE. Retinoblastoma incidence and survival in European children (1978-1997). Report from the Automated Childhood Cancer Information System project. Eur J Cancer 2006;42(13):2092-102.
5. Young JL, Smith MA, Roffers SD, et al. Retinoblastoma. In: Ries LAG, Smith MA, Gurney JG, et al (Eds). Cancer Incidence and Survival among Children and Adolescents: United States SEER Program 1975-1995. Maryland: National Cancer Institute, SEER Program;2012.
6. Kivelä T. The epidemiological challenge of the most frequent eye cancer: retinoblastoma, an issue of birth and death. Br J Ophthalmol 2009;93(9):1129-31.
7. Knudson AG Jr. Mutation and cancer: statistical study of retinoblastoma. Proc Natl Acad Sci U S A 1971;68(4):820-3.
8. Knudson AG Jr, Hethcote HW, Brown BW. Mutation and childhood cancer: a probabilistic model for the incidence of retinoblastoma. Proc Natl Acad Sci U S A 1975;72(12):5116-20.
9. Dryja TP, Morrow JF, Rapaport JM. Quantification of the paternal allele bias for new germline mutations in the retinoblastoma gene. Hum Genet 1997;100(3-4):446-9.
10. Shields JA, Shields CL. Retinoblastoma. In: Shields JA, Shields CL, eds. Intraocular Tumors. An Atlas and Textbook, 2nd edition. Philadelphia, PA: Lippincott Williams Wilkins, 2008:293-365.
11. Abramson DH, Frank CM, Susman M, Whalen MP, Dunkel IJ, Boyd NW 3rd. Presenting signs of retinoblastoma. J Pediatr 1998;132(3 Pt 1):505-8.
12. Bai S, Ren R, Shi J, et al. Retinoblastoma in the Beijing Tongren Hospital from 1957 to 2006: clinicopathological findings. Br J Ophthalmol 2011;95(8):1072-6.
13. Owoye JF, Afolayan EA, Ademola-Popoola DS. Retinoblastoma-a clinico-pathological study in Ilorin, Nigeria. Afr J Health Sci 2006;13(1-2):117-23.
14. Boubacar T, Fatou S, Fousseyni T, et al. A 30-month prospective study on the treatment of retinoblastoma in the Gabriel Toure Teaching Hospital, Bamako, Mali. Br J Ophthalmol 2010;94(4):467-9.
15. Bryne SF, Green RL. Intraocular tumors. In: Bryne SF, Green RL, eds. Ultrasound of the Eye and Orbit. 2nd edition. St. Louis, Missouri: Mosby, Inc, 2002:180-188.
16. Mafee MF, Goldberg MF, Cohen SB, et al. Magnetic resonance imaging versus computed tomography of leukocoric eyes and use of in vitro proton magnetic resonance spectroscopy of retinoblastoma. Ophthalmology 1989;96(7):965-75.
17. Murphree AI. Intraocular retinoblastoma: the case for a new group classification. Ophthalmol Clin North Am 2005;18(1):41-53.
18. Shields CL, Shields JA. Basic understanding of current classification and management of retinoblastoma. Curr Opin Ophthalmol 2006;17(3):228-34.
19. Chantada G, Doz F, Antoneli CB, et al. A proposal for an international retinoblastoma staging system. Pediatr Blood Cancer 2006;47(6):801-5.
20. Shields JA, Shields CL, De Potter P. Photocoagulation of retinoblastoma. Int Ophthalmol Clin 1993;33(3):95-9.
21. Lumbroso L, Doz F, Urbietta M, et al. Chemothermotherapy in the management of retinoblastoma. Ophthalmology 2002;109(6):1130-6.
22. Shields JA, Parsons H, Shields CL, Giblin ME. The role of cryotherapy in the management of retinoblastoma. Am J Ophthalmol 1989;108(3):260-4.

23. Wilson TW, Chan HS, Moselhy GM, Heydt DD Jr, Frey CM, Gallie BL. Penetration of chemotherapy into vitreous is increased by cryotherapy and cyclosporine in rabbits. *Arch Ophthalmol* 1996;114(11):1390-5.
24. Mendelsohn ME, Abramson DH, Madden T, Tong W, Tran HT, Dunkel IJ. Intraocular concentrations of chemotherapy following systemic or local administration. *Arch Ophthalmol* 1998;116(9):1209-1212.
25. Munier FL, Gaillard MC, Balmer A, et al. Intravitreal chemotherapy for vitreous disease in retinoblastoma revisited: from prohibition to conditional indications. *Br J Ophthalmol* 2012;96(8):1078-83.
26. Shields CL, Manjandavida FP, Arepalli S, Kaliki S, Lally SE, Shields JA. Intravitreal Melphalan for Persistent or Recurrent Retinoblastoma Vitreous Seeds: Preliminary Results. *JAMA Ophthalmol* 2014;132(3):319-25.
27. Shields CL, Manjandavida FP, Pieretti G, Arepalli SA, Jabbour P, Shields JA. Intra-arterial chemotherapy for retinoblastoma: Use as primary or secondary therapy in 70 eyes. *Ophthalmology* 2014;121(7):1453-60.
28. Shields CL, De Potter P, Himelstein BP, Shields JA, Meadows AT, Maris JM. Chemoreduction in the initial management of intraocular retinoblastoma. *Arch Ophthalmol* 1996;114(11):1330-8.
29. Murphree AL, Villablanca JG, Deegan WF 3rd, et al. Chemotherapy plus local treatment in the management of intraocular retinoblastoma. *Arch Ophthalmol* 1996;114(11):1348-56.
30. Gallie BL, Budning A, DeBoer G, et al. Chemotherapy with focal therapy can cure intraocular retinoblastoma without radiotherapy. *Arch Ophthalmol* 1996;114(11):1321-8.
31. Kaliki S, Shields CL, Shah SU, Eagle RC Jr, Shields JA, Leahey A. Postenucleation adjuvant chemotherapy with vincristine, etoposide and carboplatin for the treatment of high-risk retinoblastoma. *Arch Ophthalmol* 2011;129(11):1422-7.
32. Honavar SG, Singh AD. Management of advanced retinoblastoma. *Ophthalmol Clin North Am* 2005;18(1):65-73.
33. Hernandez JC, Brady LW, Shields JA, et al. External beam radiation for retinoblastoma: results, patterns of failure, and a proposal for treatment guidelines. *Int J Radiat Oncol Biol Phys* 1996;35(1):125-32.
34. Eagle RC Jr. High-risk features and tumor differentiation in retinoblastoma: a retrospective histopathologic study. *Arch Pathol Lab Med* 2009;133(8):1203-9.

Support provided by Hyderabad Eye Research Foundation, Hyderabad.

The funders had no role in the preparation, review or approval of the manuscript.